Winter 2012 • Volume 13, Number 1

UNIVERSITY of PITTSBURGH

neurosurgery news

Published by the University of Pittsburgh Department of Neurological Surgery • www.neurosurgery.pitt.edu

Patient Care • Teaching • Research

High-Definition Fiber Tractography: Unraveling the connections of the human brain

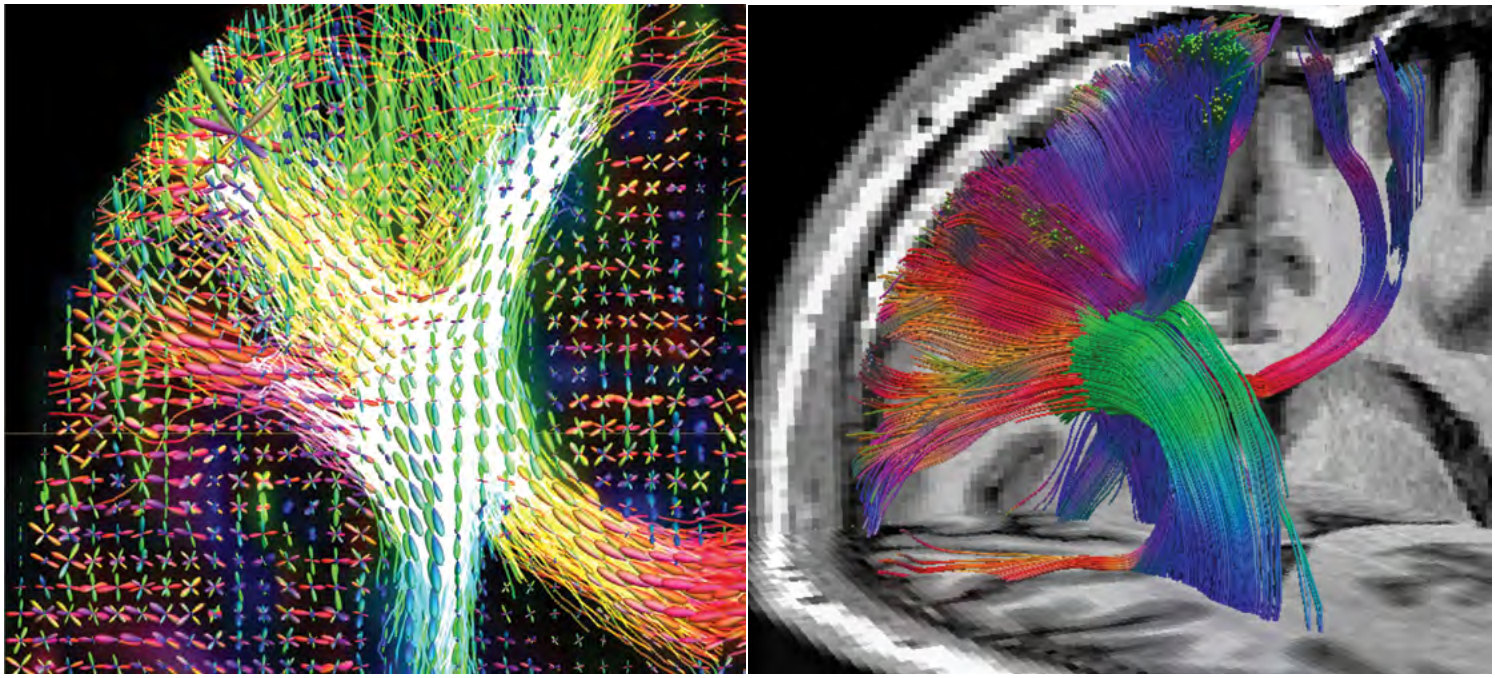

Advanced diffusion MRI techniques can measure the movement of water within the brain. The whole brain is parcellated in voxels and the direction of water within each voxel is obtained *(right figure)*. This information is then translated into a graphical representation of the water channels in the form of streamlines that are color-coded for orientation *(left figure;* green, anterior-posterior; red, lateral-medial; blue, superior-inferior*)*. The water in the brain flows within the axons, and millions of axons together form a fiber tract.

by **Juan C. Fernandez-Miranda, MD; Sudhir Pathak, MS; Walter Schneider, Ph.D.**

Nearly two decades ago, Sir Francis Crick, neuroscientist, discoverer of the DNA molecule and 1962 Nobel Prize for Medicine, wrote: "to interpret the activity of living human brains, their neuroanatomy must be known in detail. New techniques to do this are urgently needed, since most of the methods now used on monkeys cannot be used on humans."

The introduction of Diffusion Tensor Imaging (DTI) a decade ago represented a major step toward this goal. DTI is a Magnetic Resonance Imaging (MRI) technique that measures the diffusion of water within the axons ("wires") of the brain. The information obtained with DTI-MRI is then processed mathematically to obtain a graphic representation of the water channels or tracks within the brain, a method called fiber tractography. The ability to non-invasively map fiber tracts in the living human brain will facilitate numerous applications in the diagnosis and treatment of brain disorders, and for this reason, the National Institute of Health (NIH) stated that the Human Connectome Project (the complete description of the "wiring" of the human brain) is one of the great scientific challenges for the upcoming decade.

We initiated our studies of the brain fiber tracts using DTI almost a decade ago, and we demonstrated that DTI provides accurate reconstruction of the major stem of fiber tracts, in agreement with classical and contemporary neuroanatomical studies. DTI, however, has several limitations since it is unable to solve the crossing of fibers and determine with accuracy the origin and destination of fibers, producing multiple artifacts and false tracts. These limitations significantly decrease the accuracy of the technique in the clinical setting.

For the last four years, our group at University of Pittsburgh has focused on optimizing brain fiber mapping techniques to obtain what we refer to as High Definition Fiber Tracking (HDFT). HDFT is a novel combination of processing, reconstruction, and tractography methods that can track several hundred thousand fibers from cortex, through complex fiber crossings, to cortical and subcortical targets with at least millimeter resolution. This disruptive technique has been applied in dozens of normal subjects and more than a hundred neurosurgery patients.

In this newsletter, we aim to introduce to the community our results with the application of HDFT for the study of structural connectivity in normal subjects, and we present our experience with the clinical application of HDFT for neurosurgery patients. This remarkable innovation has been possible at University of Pittsburgh thanks to a unique collaboration between clinicians and researchers with expertise in diverse disciplines such as neurosurgery, neuroanatomy, psychology, computer science, mathematics, and physics.

(continued on back cover)

CHAIRMAN'S MESSAGE

HDFT latest game-changer in neurosurgical field

The history of the Department of Neurological Surgery at the University of Pittsburgh has been highlighted by the development and implementation of important advances in neurosurgery that have altered the manner in which neurosurgical care is delivered. Initially, these changes were viewed with apprehension and, at times, have taken decades to be widely accepted into neurosurgical practice. Implementation of these novel approaches has ultimately resulted in paradigm shifts for mainstream neurosurgery.

The most notable examples of such transforming technical advances include microvascular decompression for trigeminal neuralgia, hemifacial spasm and other neurovascular compressive pathologies; skull base surgery for complex skull base pathologies; radiosurgery for vascular malformations, tumors and functional disorders; and finally endoscopic endonasal surgery for anterior skull base lesions.

Each one of these advances, in their own way, revolutionized the care of neurosurgical patients. These approaches provided options to patients who, either had no options, or significantly reduced the overall morbidity and mortality for the treatment of their specific diseases. We are extremely proud of the remarkable impact these advances have made in our field.

A new game-changer in the care and management of neurosurgical patients is the application of High Definition Fiber Tractography (HDFT). As described in this issue of our newsletter, the broad application of HDFT for surgical planning, intraoperative management and for prognosticating head trauma is far reaching. As neurosurgeons, having the ability to see what we have never been able to see (i.e. the actual connections within the brain), provides opportunities that we previously could only have imagined. The potential of HDFT is boundless and is now changing the practice of neurosurgery in Pittsburgh. I look forward to its broad implementation in the years to come.

Robert M. Friedlander, MD, MA
Chairman, Department of Neurological Surgery
UPMC Endowed Professor of Neurosurgery & Neurobiology
University of Pittsburgh School of Medicine
University of Pittsburgh Medical Center

Some Key Department Phone Numbers

Brain Function & Behavior	(412) 647-7744	Movement Disorders	(412) 647-7744
Brain Trauma Research Ctr	(412) 647-0956	Neurotrauma	(412) 647-1025
Brain Tumor	(412) 647-2827	Neurosurgical Oncology	(412) 647-8312
Carotid Disease	(412) 647-2827	Pediatric Neurosurgery	(412) 692-5090
Cerebrovascular	(412) 647-2827	Referrals	(412) 647-3685
Clinical Neurophysiology	(412) 647-3450	Residency Program	(412) 647-6777
CyberKnife	(412) 647-1700	Speakers Bureau	(412) 647-3685
Donations	(412) 647-7781	Spine	(412) 802-8199
Endonasal Surgery	(412) 647-6778	Synergy	(412) 647-9786
Endovascular	(412) 647-7768	UPMC News Bureau	(412) 647-3555
Gamma Knife	(412) 647-7744	UPMC Presbyterian	(800) 533-8762
MEG Brain Mapping Center	(412) 648-6425	Website	(412) 647-7931

UNIVERSITY of PITTSBURGH
neurosurgery news

Editor: Douglas S. Kondziolka, MD • **Production Editor:** Paul Stanick
Issue Editor: Juan Carlos Fernandez-Miranda, MD

Newsletter .pdf archive is available on our website at **www.neurosurgery.pitt.edu/news/neuronews**
General Phone & Referrals: (412) 647-3685 • **Department e-mail:** neuroinfo@upmc.edu
Department YouTube Channel: www.youtube.com/neuroPitt

Department Address: UPMC Presbyterian, 200 Lothrop Street/Suite B-400, Pittsburgh, PA 15213

Using high resolution white matter mapping to detect traumatic brain injury

***by* Samuel Shin; David Okonkwo, MD, PhD; Walter Schneider, PhD; Timothy Verstynen**

There are an approximately 1.7 million cases of traumatic brain injury (TBI) each year in the U.S. and current medical imaging (CT, MRI, DTI) rarely (5-30%) visualizes or detects damage caused by most TBI. Even in cases with devastating consequences (e.g., persistent coma) current imaging techniques do not provide information about the specific degree and location of axonal damage. The team at the University of Pittsburgh Medical Center Department of Neurosurgery developed a novel imaging modality, High Definition Fiber Tracking (HDFT), based on diffusion technology. HDFT enables neuroimaging of forty brain tracts and unveils the details of focal injury at a resolution of 2 millimeters that has not been demonstrated by conventional imaging techniques. The details of white matter damage identified by HDFT may be useful for prognostic purposes and aid in rehabilitation strategies customized for each patient in the future.

Current techniques of imaging TBI mainly involve CT and MRI. While CT can only detect hemorrhage or encephalomalacia, MRI has shown some promise through diffusion imaging methods, which are sensitive to underlying white matter integrity. A diffusion imaging modality known as diffusion tensor imaging (DTI) has gained significant interest for its potential utility for TBI imaging in the last decade. However DTI still lacks the fine resolution for distinguishing white matter tracts and is prone to false representation of the tract anatomy. 648-6425

The members of the Pittsburgh High Definition Fiber Tracking Group analyzed the fiber tract damage in a case of a 32-year old male who was involved in a motor vehicle accident resulting in a severe TBI. (This work has been accepted for publication in an upcoming issue of the *Journal of Neurosurgery*). The patient initially had a large right-sided basal ganglia hematoma which correlated with dense left hemiparesis. He underwent standard CT and MRI scanning, along with HDFT at four months and ten months. At six months post injury, lower limb weakness had resolved and only left upper extremity weakness was present. The DTI fractional anisotropy (FA) map, a measure of the general integrity of white matter post injury, showed reduced signal suggesting axonal injury. This FA map provided a low resolution representation of the injured tract and did not show the projection field of the tract. To compare to DTI, HDFT was used to track corona radiata, cingulum, and superior longitudinal fasciculus.

Analysis of HDFT data identified 67% difference in tract volume between the right and left corona radiata *(image below)*, whereas cingulum and superior longitudinal fasciculus had no major differences between the two sides. Further analysis of the data identified right corona radiata fibers projecting to the central sulcus and precentral gyrus to have 54% loss compared to the left. Right corona radiata fibers projecting to premotor areas had 97% loss compared to the left. Finally, corticospinal tract fibers of the patient were analyzed and compared to the tracts of six age and gender matched control subjects to identify large loss of fibers at the level of midbrain *(figure below)*. Major losses were found predominantly in the tracts projecting from the ventrolateral area of the primary motor cortex, which is responsible for upper extremity control.

These test findings suggest that HDFT may one day provide a definitive imaging modality for TBI. This will also become important in the future as various therapeutic options for TBI will become available, and optimal management of TBI will need detailed characterization of injury in each case.

DTI and structural MRI did not convey the spatial specificity and the degree of damage to the descending motor pathways as HDFT did. With HDFT, we were able to visualize the specific location and quantify the degree of white matter injury responsible for the patient's upper extremity weakness. This novel approach successfully detected, visualized, and quantified damage when previous methods (CT, structural MRI, and DTI) did not provide these details. Although HDFT is an evolving technology that is still at an early stage of development, this analysis showed various advantages it provides over conventional techniques for TBI imaging. These advantages may indicate the clinical utility of HDFT for TBI cases in the near future as the imaging quality of HDFT is further refined. •

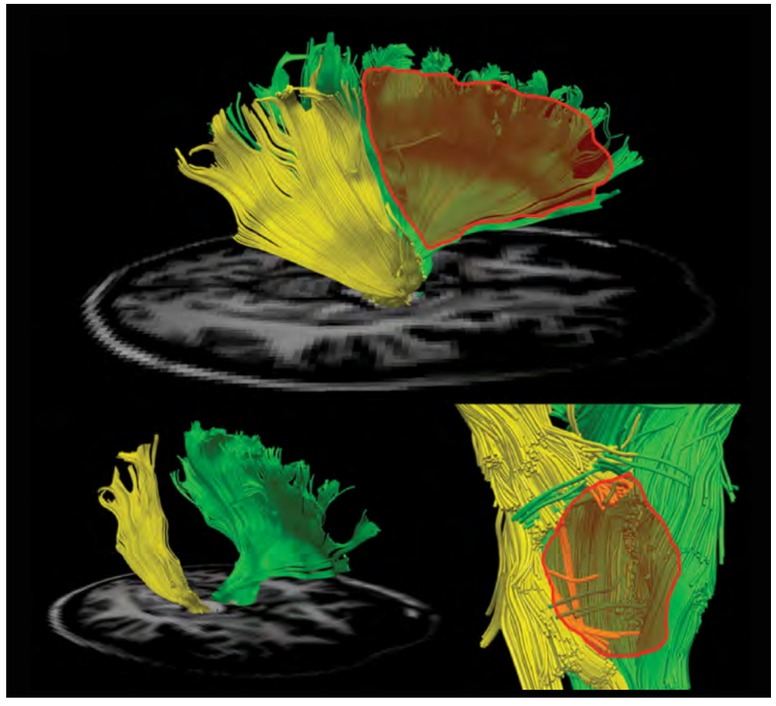

Lateral view of the corona radiata of TBI subject (a) shows fiber tract loss on the right side (outlined in red). Oblique view (b) and magnified view of the tracts at the level of midbrain (c) reveals the details of fiber losses.

HDFT, endoscopic port surgery synergistic in management of deep brain tumors

by Johnathan Engh, MD; Sudhir Pathak, MS; Juan C. Fernandez-Miranda, MD

Deep brain tumors are often not considered for surgical removal because of concern of morbidity related to tumor access and visualization. However, it is known that surgical resection can improve both neurological and oncological outcomes for patients with brain tumors. The Neuroendoport[SM] is a minimally invasive access tool for deep tumor resection that has been implemented in the removal of deep brain tumors using a technique called endoscopic port surgery (EPS). It is a transparent cylindrical retractor, 11.5 mm in diameter and of varying length, which facilitates deep brain access with minimal brain trauma while still allowing for bimanual microsurgery to remove the tumor. At UPMC, a significant experience has been developed using the Neuroendoport to remove deep tumors.

Prior experience with endoscopic port surgery has demonstrated that high definition fiber tracking (HDFT), a MRI-based technique of white matter imaging, can be used to guide cannulation of a tumor using an endoscopic port, minimizing damage to functional surrounding nerve fascicles. This technique helps to ensure that critical fiber tracts, such as the corticospinal tract (CST), the optic radiations, or the arcuate fasciculus are not damaged by the port during deep brain surgery.

Illustrative Case

A 47-year-old, right-handed woman was referred for a surgical evaluation of a right thalamic glioblastoma. The patient initially presented with headaches, left-sided numbness and left hemianopia. Following diagnostic biopsy, she underwent concomitant temozolomide chemotherapy with radiation therapy followed by temozolomide monotherapy. After six months of therapy, the patient was in her usual state of health until the past few weeks, during which she developed worsening headaches, worsening left-sided numbness and weakness, as well as some mild confusion and some intermittent visual hallucinations with lack of clarity of vision in the right visual hemifield. She was already blind in the left visual hemifield.

On examination, the patient was awake and alert. She was oriented x3. She had a slight left facial droop, left-sided pronator drift, minimal left-sided weakness on the order of 4 out of 5. She also had a mild proprioceptive deficit. She had a complete left hemifield cut, as well as some mild right visual field disturbance.

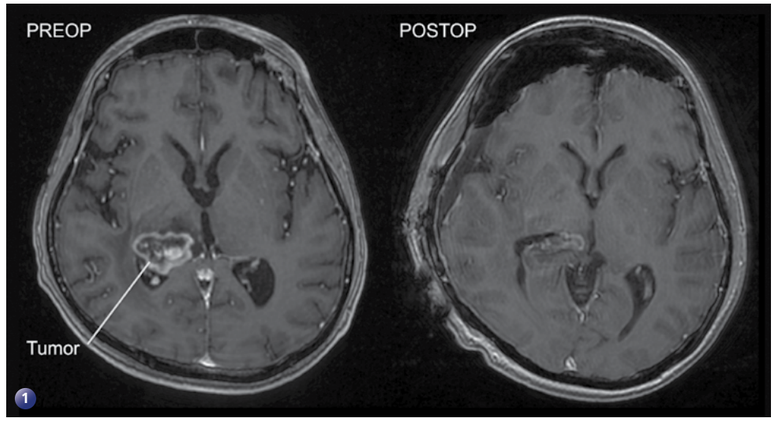

Figure 1: **Preoperative and postoperative T1-weighted axial sections with contrast showing a subtotal resection of a right posterior thalamic tumor.**

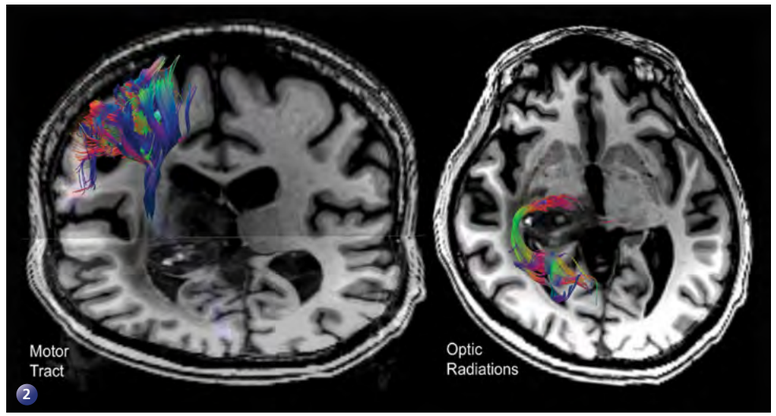

Figure 2: **HDFT reconstruction of the fiber tracts in this patient showed the location of the cortico-spinal (motor) tract just anterior and lateral to the tumor, and the optic radiations (visual system) just lateral and inferior to it. The surgical endoport trajectory was planned accordingly.**

MRI scans demonstrated a peripherally enhancing, centrally necrotic mass within the right thalamus with significant surrounding T2 signal prolongation. HDFT scans were performed and the CST was isolated from these scans. Given the patient's neurologic deterioration, surgery was recommended via a transtemporal approach using EPS technique. HDFT images were used to guide tumoral cannulation, ensuring that the entry into the tumor was inferoposterior to the CST. Post-operative MRI and HDFT images confirmed an excellent tumor debulking with no additional loss of CST fibers, *(figure 2)*.

Post-operatively, the patient's headache and right visual field disturbances improved. Her left hemiparesis improved minimally. The left hemianopia remained. She returned home for rehabilitation prior to additional adjuvant therapy.

HDFT and EPS are synergistic in the surgical management of deep brain tumors. Such tools facilitate treatment options that are generally not feasible using conventional MRI scans and conventional microsurgical techniques. Further experience will help to delineate the breadth of applicability of this technique for challenging deep brain tumor patients. •

Intra-operative use of HDFT with image-guidance valuable in awake craniotomy for tumor resection

by Arlan Mintz, MD; Johnathan Engh, MD; Sudhir Pathak, MS; Juan C. Fernandez-Miranda, MD

Current strategies for the surgical treatment of malignant brain tumors are directed towards maximal tumor resection while preserving neurological function. Injury to adjacent critical brain tissue can occur during the approach through the cortex and also via injury to eloquent fiber tracts that surround the tumor. However, fiber tract visualization surrounding the tumor is significantly limited using standard MRI imaging techniques, even with diffusion tensor imaging (DTI). In contrast, we have found that high definition fiber tracking (HDFT) provides fiber tracking imaging that is more robust in the setting of vasogenic edema and has the ability to deal with fiber crossings. Here, we present a case where we utilized HDFT within the operating room to visualize and preserve the motor fibers during tumor resection.

A 60-year-old physician presented with complaints of headache, left-sided incoordination and mild motor weakness. Magnetic resonance imaging (MRI) scans demonstrated a heterogeneously enhancing mass surrounded by substantial peri-tumoral T2 signal change, *(figure 1)*. Given the presumptive diagnosis of a high-grade glioma, surgical resection was recommended. The key concern was the presence of the tumor abutting and possibly involving the corticospinal tract (AKA motor tract) at the anterior portion of the tumor. Injury to these fibers would result in a significant risk for motor deficit. In order to better visualize peri-tumoral motor fibers, the patient underwent HDFT prior to surgical resection. We found that the motor fibers appeared to be displaced anteriorly by the tumor, which infiltrated much of the parietal lobe, *(figure 2)*.

We elected to resect the tumor via an awake craniotomy with cortical mapping, which would facilitate real-time monitoring for any neurologic deficit. The HDFT images were transferred into our image-guidance navigation software by an image uplink interface to allow them to be tracked during surgery. The fiber tract imaging was crossed referenced to the anatomical images of the T1 MRI. As expected, intra-operative cortical mapping identified that the motor cortex was anterior to the tumor. A cortisectomy was made immediately posterior to the motor cortex, and tumor was identified and the resection started using an ultrasonic aspirator. The navigation workstation showed the motor fibers either projected to the skin surface of the patient or overlaid on the structural MRI of the patient as the tumor resection proceed, *(figure 3)*. The anterior portion of the resection approached the motor fibers as visualized on HDFT on the image guidance system, but these fibers were all left intact. Post-operatively, the patient was neurologically stable and her motor symptoms improved to normal within weeks. Diagnosis was made of a glioblastoma multiforme, and the patient underwent adjuvant temozolomide with concurrent fractionated irradiation followed by temozolomide monotherapy. One year after surgical resection, her disease remained reasonably controlled, and her Karnofsky performance score was 90, with preserved motor function.

Uploading fiber-tracking data into image guidance is a difficult task, due to software compatibility issues. The use of an image uplink interface provides a solution to this problem, and we are now able to utilize image-guidance system with imaging of fiber tracts of interest with high fidelity and extreme accuracy. This ability to have in-depth analysis of peri-tumoral fiber tracts for tumors in and around the motor strip or speech areas imported into our navigation system allows for the ability to track and avoid these critical pathways. In the present case during the operation, we were able to correlate the findings of the awake cortical mapping with the localization of the motor fibers as provided by the HDFT-based image guidance. The use of HDFT combined with the techniques of awake craniotomy had a dramatic impact on the pre-operative planning and intra-operative tumor resection of this patient. •

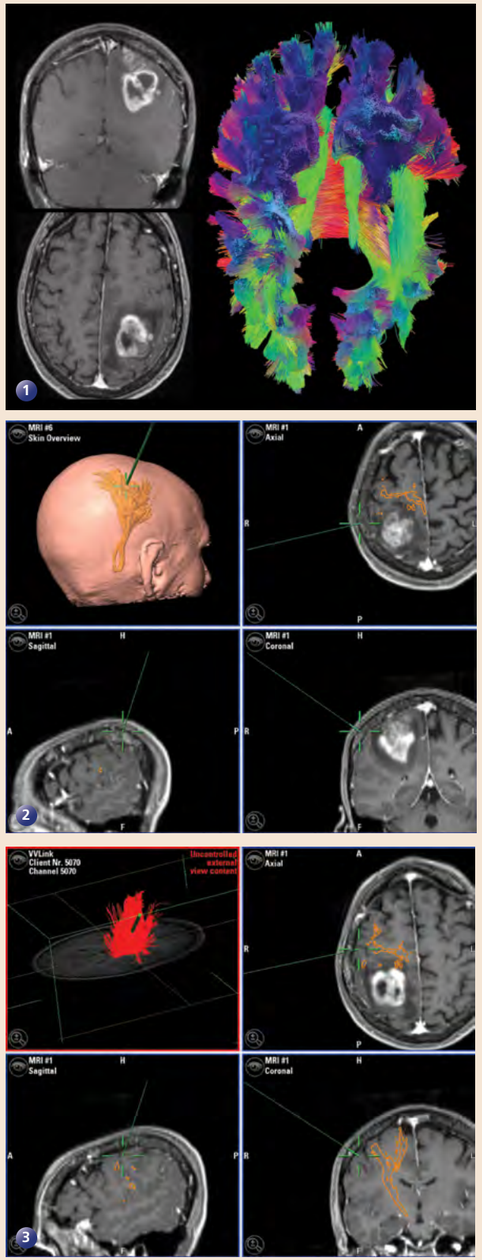

Figure 1: Upper panel: Preoperative coronal and axial T1 weighted sections showing a contrast-enhancing and necrotic tumor near the motor region. The HDFT reconstruction confirmed the spatial relationship of the tumor with adjacent fiber tracts. Figure 2: The cortico-spinal (motor) tract was segmented and incorporated into the intraoperative navigation system for accurate localization. Figure 3: the fibers of the motor tract (red) were identified during the operation, and their location was confirmed with the use of intraoperative cortical electrical mapping.

HDFT provides key edge in presurgical planning of brainstem cavernomas

by **Robert M. Friedlander, MD; Juan C. Fernandez-Miranda, MD; Amir Faraji**

Brainstem cavernomas are one of the most complex challenges a neurosurgeon can face. The natural history of such lesions must be weighed against the risk of surgical resection. Surgical access to the brainstem is extremely delicate given the intricacy and eloquence of the fiber tracts and nuclei that form its structure. Historically resection has been fraught with significant rates of complications. One of the complexities is accessing the brainstem is that it is not predictable in which direction has the cavernomas displaced functional fibers. Here we report the innovative application of HDFT to map the fiber tracts within the brainstem and around a cavernoma to safely access and remove the lesion. HDFT provides information on the remaining normal fibers in relation to the cavernomas.

Understanding this relationship provides the surgeon the ability to plan a trajectory through the brainstem which maximizes the safety of resection of such lesions. Tipping the balance towards increased safety and efficacy allows for the ability to offer a therapy that is overall safer than the natural history of the untreated malformation. We have used HDFT to resect a number of a different types of lesions in eloquent areas of the brain and brainstem. Here we describe a case of the first cavernous malformation removed from the brainstem, using the information provided by HDFT to plan the trajectory and execute the resection.

A 24-year-old female patient experienced a hemorrhage from a previously undiagnosed left pontomesencephalic cavernous malformation, and was subsequently admitted to an outside center. She suffered from a dense right upper and lower extremity hemiparesis, a right gaze preference, and moderate dysarthria. Brain MRI demonstrated a left cavernous malformation within the brainstem. Given the location of the lesion the neurosurgeons recommended conservative management. After approximately one week, she was transferred to a rehabilitation facility where her speech progressively improved and the hemiparesis persisted. While at the rehabilitation facility, she became lethargic and developed a new left gaze preference with diminished mental status. She was emergently transferred to our institution for neurosurgical intervention.

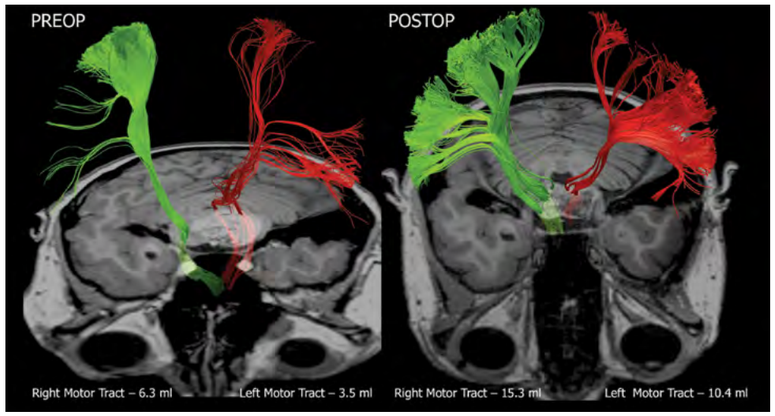

The preoperative HDFT reconstruction of the motor tracts showed the posterior displacement and decreased number of fibers of the left tract (red) when compared to the right tract (green). Postoperatively, the left motor tract (red) recovered most of its normal position and volume of fibers, and the right tract (green) also showed a volume increase as a consequence of the surgical treatment.

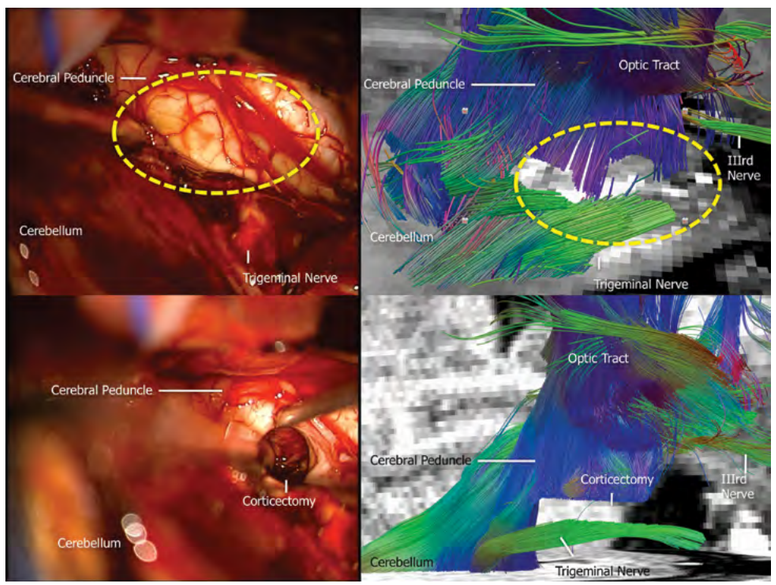

Intraoperative photographs (upper and lower right) to be compared with the preoperative (upper left) and postoperative (lower left) HDFT reconstructions. The information provided by the HDFT study was used to plan the trajectory and entry point into the brainstem (lower right and left figures).

Upon arrival the patient was awake, alert and oriented to person, place, and time. She had a right facial droop and double vision. She developed significant weakness of the right arm and leg. She had slurred speech and her tongue deviated towards the right. Brain MRI demonstrated that the cavernous malformation had bled one more time, and had more swelling around it. Given the aggressive nature of this malformation we recommended that the lesion be resected. The challenges of such a procedure are access as well as deciding the specific location to enter into the brainstem. Once inside the

Example Improved Patient Outcome Through HDFT

(continued from previous page)

brainstem, understanding the location of the remaining normal structures provides the ability to remove the lesion with the greatest degree of safety.

To gather information as to the location of the normal fibers, the patient underwent on MRI study with HDFT imaging analysis. HDFT indicated severe deformation of the ipsilateral motor tract, with apparent disruption of some of its fibers with significant posterior displacement of a large number of motor fibers.

Based on this tractography data and image guidance correlation, the surgical approach was carefully considered and a trajectory was selected to provide more immediate access to the intra-parencymal hematoma and cavernous malformation, while preserving the intact motor fibers. This trajectory involved accessing the brainstem just in front of the motor fibers that were posteriorly displaced by the hematoma and cavernous malformation. In accordance with this pre-operative planning, the patient underwent a left-sided frontotemporal, subtemporal transpetrous approach to access the pontomesencephalic cavernous malformation under image guidance. The lateral surface of the midbrain was visualized with a surgical microscope and a subtle yellow stain was observed, suggesting that this may be the most superficial location of the malformation. A small opening was made into the brainstem where the cavernous malformation was readily encountered. The hematoma and cavernous malformation were completely resected.

Her immediate post-operative examination revealed improvement in her double vision, her facial droop, as well as her right sided weakness. Her sensation remained intact throughout. Post-operative HDFT study was completed to evaluate the impact of surgical resection on the motor fibers, demonstrating preservation of the posteriorly displaced motor fibers and transection of the previously disrupted fibers, as expected.

Over the course of the next six months, the physical displacement of white matter fibers continued to resolve, as revealed by a third HDFT scan. Moreover, her neurological examination continued to progressively improve. She is able to perform her activities of daily living with minimal-to-no assistance.

HDFT provided us an edge in order to be able to offer a procedure in this specific young patient. Knowing the exact location of critical fibers within the brainstem provides us the ability to approach and remove these lesions with much higher degree of safety. The surgeon can not see these fibers when operating under the microscope. However knowing where they are located allowed us to provide the excellent result to our patient. •



Robert Friedlander, MD, with brainstem cavernoma patient Ashly Hunt.

news & NOTES

Monaco to Receive Leksell Radiosurgery Award

PGY-6 resident Edward A. Monaco, III, MD, PhD, has been selected to receive the 2012 Leksell Radiosurgery Award by the AANS/CNS Section on Tumors. The award, in recognition for Dr. Monaco's paper "The risk of leukoencephalopathy after whole brain radiation therapy plus radiosurgery versus radiosurgery alone for metastatic lung cancer," will be presented at the 2012 AANS Annual Scientific Meeting in Miami, FL, in April.

Study Ranks Pitt at Top for Stereotactic Research

The *British Journal of Neurosurgery* published findings online in November of a bibliometrics study showing the University of Pittsburgh ranking first in the world in global scientific production in stereotactic-related research. The study—using data from 1993 through 2008—sought "to provide insights on the characteristics of the stereotactic related research patterns, tendencies, and methods that might exist in the papers, as well as in leading countries and institutes." According to the paper, "the results analyzed by this bibliometric method can show the research performance, significant events and major inventors, those attributed to stereotactic neurosurgery, and trend of stereotactic related research."

In the Media

• **L. Dade Lunsford, MD,** appeared on a *Journal of Neurosurgery* podcast November 11 summarizing the findings presented in a landmark six-part journal article on the Center of Image-Guided Neurosurgery's 20-year arteriovenous malformations experience.

• **Peter C. Gerszten, MD**, was featured in the Spanish publication *Diaro Medico* article "Evaluar al paciente, clave en el manejo de columna vertebal." The national newspaper is distributed to all hospitals in Spain.

Prominent Lectures and Appearances

• **Joseph Maroon, MD**, presented a keynote address at the 19th Annual World Congress on Anti-Aging and Aesthetic Medicine held in Las Vegas, NV, December 10. The title of his talk was, "A Metabolic Approach to Malignant Brain Tumors."

• **Peter C. Gerszten, MD**, was the invited keynote speaker of the First Spanish Symposium of Radiosurgery held in Castellon, Spain, January 27, 2012.

• **Juan C. Fernandez-Miranda, MD**, was the invited keynote speaker at the International Neuroanatomy Symposium held at University of Florida in Gainesville, January 28 to celebrate the 40th anniversary of Albert Rhoton, MD, at the university.

Congratulations

• **Elizabeth Tyler-Kabara, MD, PhD**, and **Mandeep Tamber, MD, PhD**, are now diplomates of the American Board of Pediatric Neurological Surgery.

• **Marianna Hegedus** received her MBA from Chatham University in December.

Welcome

Melissa Hart-Gibson, front desk receptionist; **Yalikun Suofu, PhD**, postdoctoral fellow; **Lisa Pareso**, J. William Bookwalter group. •

UNIVERSITY of PITTSBURGH
neurosurgery news

Department of Neurological Surgery
University of Pittsburgh Medical Center
UPMC Presbyterian/Suite B-400
200 Lothrop Street
Pittsburgh, PA 15213
(412) 647-3685
neuroinfo@upmc.edu

www.neurosurgery.pitt.edu

Non-Profit
Organization
U.S. Postage
PAID
Permit #4166
Pittsburgh, PA

UPMC

Recognized as an honor roll member of *U.S.News & World Report's* 'America's Best Hospitals' 2010-11

WINTER 2012 • VOLUME 13, NUMBER 1

High-Definition Fiber Tractography: Unraveling the connections of the human brain

(continued from page 1)

Solving Enigmas: the Anatomy of Language

HDFT provides a unique opportunity to study the connectivity of certain brain areas and functions that are largely unknown. Our studies on the arcuate tract, which is a major fiber system that interconnects different speech centers, have revealed an intriguing arrangement of the language circuitry: an inner semicircumferential tract that interconnects both primary speech centers (expressive or Broca's and receptive or Wernicke's), and a pair of outer parallel semicircumferential tracts that interconnect secondary or supplementary speech areas *(figure at right)*. There is no doubt that a better delineation of the intricate structure of the human brain will improve our understanding of its complex functions, such as language, and the treatment of disorders of the human brain. •

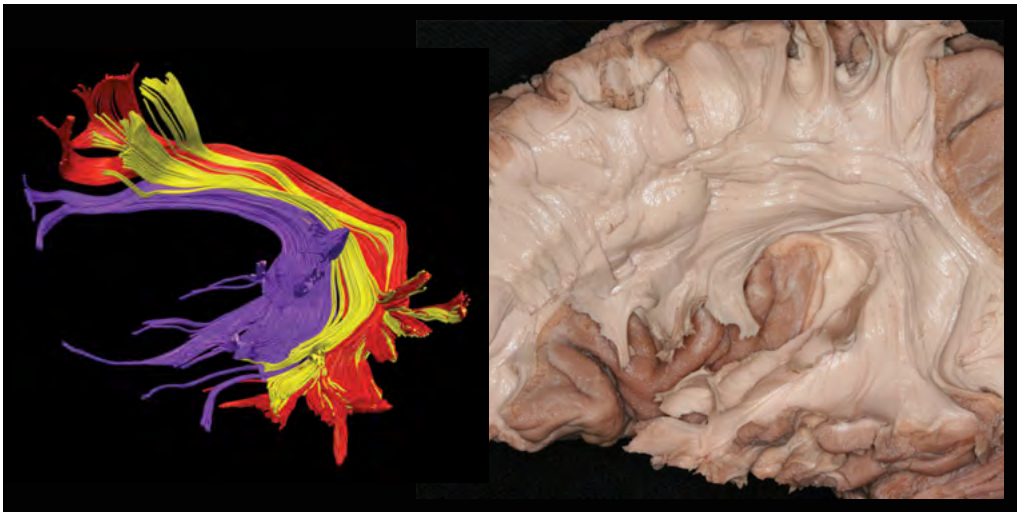

HDFT reconstruction (right) and anatomical fiber microdissection (left) of the left arcuate tract. With HDFT we can investigate the structural connectivity between multiple areas of the human brain. The arcuate tract is considered the "language" tract because interconnects distant language centers. Our investigations have revealed a complex network formed by several cortical centers interconnected by multidirectional pathways, organized in a concentric and parallel fashion. The inner or primary circuit (purple) is thought to be mostly related to the phonological aspect of language, while the outer circuits (red, yellow) are in charge of the semantic aspect of language. Further investigation is needed to ascertain the complete structure of the language system in the human brain