

Using high resolution white matter mapping to detect traumatic brain injury

by Samuel Shin; David Okonkwo, MD, PhD; Walter Schneider, PhD; Timothy Verstynen

There are an approximately 1.7 million cases of traumatic brain injury (TBI) each year in the U.S. and current medical imaging (CT, MRI, DTI) rarely (5-30%) visualizes or detects damage caused by most TBI. Even in cases with devastating consequences (e.g., persistent coma) current imaging techniques do not provide information about the specific degree and location of axonal damage. The team at the University of Pittsburgh Medical Center Department of Neurosurgery developed a novel imaging modality, High Definition Fiber Tracking (HDFT), based on diffusion technology. HDFT enables neuroimaging of forty brain tracts and unveils the details of focal injury at a resolution of 2 millimeters that has not been demonstrated by conventional imaging techniques. The details of white matter damage identified by HDFT may be useful for prognostic purposes and aid in rehabilitation strategies customized for each patient in the future.

Current techniques of imaging TBI mainly involve CT and MRI. While CT can only detect hemorrhage or encephalomalacia, MRI has shown some promise through diffusion imaging methods, which are sensitive to underlying white matter integrity. A diffusion imaging modality known as diffusion tensor imaging (DTI) has gained significant interest for its potential utility for TBI imaging in the last decade. However DTI still lacks the fine resolution for distinguishing white matter tracts and is prone to false representation of the tract anatomy. 648-6425

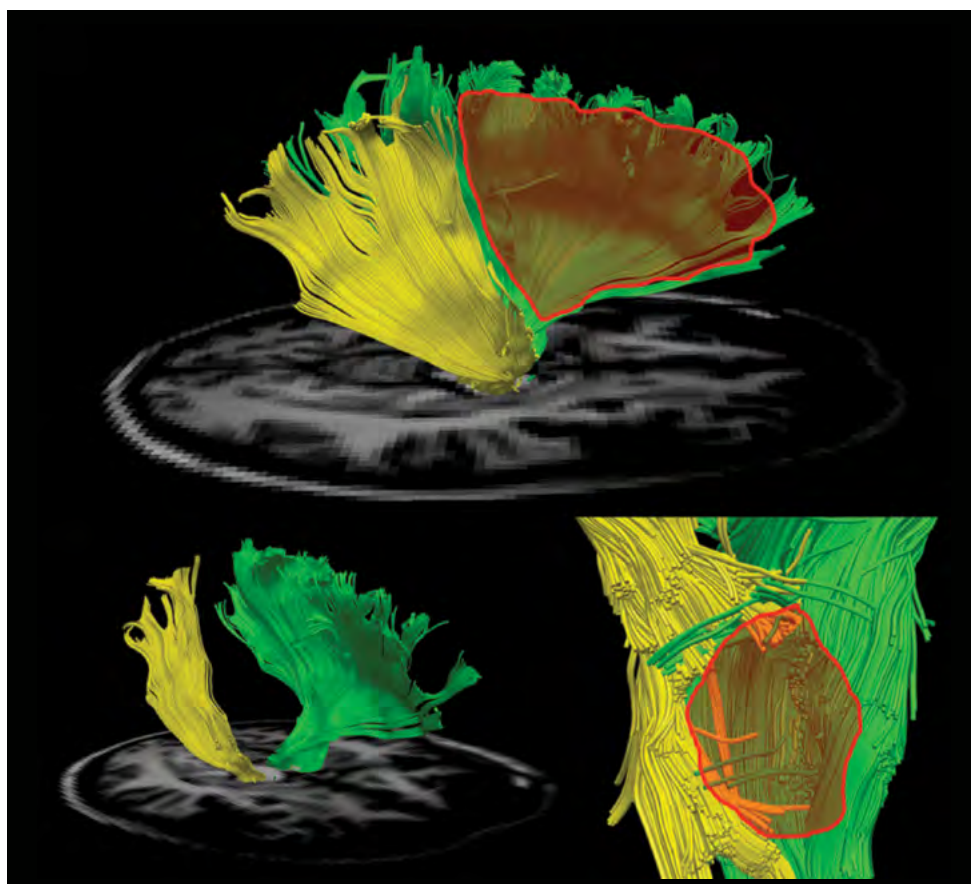
The members of the Pittsburgh High Definition Fiber Tracking Group analyzed the fiber tract damage in a case of a 32-year old male who was involved in a motor vehicle accident resulting in a severe TBI. (This work has been accepted for publication in an upcoming issue of the *Journal of Neurosurgery*). The patient initially had a large right-sided basal ganglia hematoma which correlated with dense left hemiparesis. He underwent standard CT and MRI scanning, along with HDFT at four months and ten months. At six months post injury, lower limb weakness had resolved and only left upper extremity weakness was present. The DTI fractional anisotropy (FA) map, a measure of the general integrity of white matter post injury, showed reduced signal suggesting axonal injury. This

FA map provided a low resolution representation of the injured tract and did not show the projection field of the tract. To compare to DTI, HDFT was used to track corona radiata, cingulum, and superior longitudinal fasciculus.

Analysis of HDFT data identified 67% difference in tract volume between the right and left corona radiata (*image below*), whereas cingulum and superior longitudinal fasciculus had no major differences between the two sides. Further analysis of the data identified right corona radiata fibers projecting to the central sulcus and precentral gyrus to have 54% loss compared to the left. Right corona radiata fibers projecting to premotor areas had 97% loss compared to the left. Finally, corticospinal tract fibers of the patient were analyzed and compared to the tracts of six age and gender matched control subjects to identify large loss of fibers at the level of midbrain (*figure below*). Major losses were found predominantly in the tracts projecting from the ventrolateral area of the primary motor cortex, which is responsible for upper extremity control.

These test findings suggest that HDFT may one day provide a definitive imaging modality for TBI. This will also become important in the future as various therapeutic options for TBI will become available, and optimal management of TBI will need detailed characterization of injury in each case.

DTI and structural MRI did not convey the spatial specificity and the degree of damage to the descending motor pathways as HDFT did. With HDFT, we were able to visualize the specific location and quantify the degree of white matter injury responsible for the patient's upper extremity weakness. This novel approach successfully detected, visualized, and quantified damage when previous methods (CT, structural MRI, and DTI) did not provide these details. Although HDFT is an evolving technology that is still at an early stage of development, this analysis showed various advantages it provides over conventional techniques for TBI imaging. These advantages may indicate the clinical utility of HDFT for TBI cases in the near future as the imaging quality of HDFT is further refined. •



Lateral view of the corona radiata of TBI subject (a) shows fiber tract loss on the right side (outlined in red). Oblique view (b) and magnified view of the tracts at the level of midbrain (c) reveals the details of fiber losses.